

Modern Disease with Old Treatment Cure : A Case Report with Review

Dr. Anusha Ch, Dr. Garata Raju, Dr. Ramani, Dr. U. S. B. Lakshmi, Dr. R. N. Raviteja Reddy

Department of Prosthodontics, Lenora Institute of Dental Sciences, Rajahmundry, Andhra Pradesh, India

ABSTRACT

A Prosthodontist's role is not limited to removable, fixed or implant supported dentures. The treatment of sleep Apnoea with the use of oral appliances has been underutilized and traditionally, they have been provided mainly in a hospital setup. This article reviews the available options for the treatment of sleep-related breathing disorders with an emphasis on oral appliance therapy and a case report of a patient suffering from sleep apnea.

Keywords : Prosthodontist, Sleep Apnoea, Oral Appliance Therapy

I. INTRODUCTION

Sleep is a physiologic and behavioral state characterized by partial isolation and reduced responsiveness to sensory stimuli which can be readily and quickly relieved. Physiologic functions. There is lessening in muscle tone, Heart rate, Breathing frequency, Blood pressure and temperature, Brain activity. Sleep apnea is a potentially serious sleep disorder in which breathing repeatedly stops and starts. 1

II. METHODS AND MATERIAL

Classification of Sleep Apnea²

-Obstructive sleep apnea: in this type the throat muscles fail to relax. It is seen in 4% males and 2% females.

-Central sleep apnea- In this type the respiratory muscles fail to relax since the brain doesn't send signals.

-Mixed sleep Apnea: It is a combination of both obstructive and central sleep apnea. Also known as emergent sleep apnea.

Etiology and Pathogenesis³

Collapsing of tongue back into the pharynx during sleep since the throat muscles fail to relax (Fig 1). Therefore the patient exerts more pressure for breathing air in and out which results in vibration of soft palate and snoring.

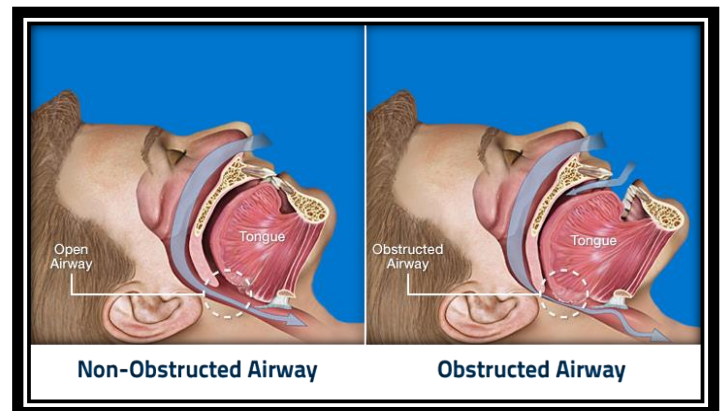


Figure 1: Non Obstructed and Obstructed airway

Clinical Features

- Snoring
- Nocturnal choking or gasping
- Insomnia
- Day time fatigue
- Depression
- People who are obese

Diagnosis

- Polysomnography
- Epworth sleepiness scale
- Multiple sleep latency test
- Mallampati score
- Lateral cephalometric radiographs
- Fiberoptic nasopharyngoscopy

Management of OSA

- Conservative method
 - Positive airway pressure

- Pharmacological treatment
- Behavioral modification
- Alteration in sleeping position
- Oral appliance therapy
- Surgical invasive
 - Genioglossus and tongue advancement therapy
 - Maxillomandibular advancement
 - Laser assisted uvuloplasty
 - Tracheostomy
 - Uvulopalatopharyngoplasty

Three basic concepts² were proposed in the literature for an oral appliance to modify the airway which can be used alone or in combination depending on where the airway obstruction occurred:-

- a) Soft palate lifting appliances
- b) Tongue retaining appliances
- c) Mandibular advancement / repositioning appliances

1. Soft palate lifting appliance:

Given where there is incompetency of soft palate. It lifts the soft palate from falling down thus maintaining unobstructed air way.

2. Uvula lift appliance:

Similar to soft palate lift appliance. Given where elongated or bifid uvula is the reason for obstruction of upper airway.

3. Velopharynx lift appliance:

Lifts the soft palate, uvula and the surrounding structures. Usually given in class III soft palate conditions.

4. Nasopharyngeal aperture guard appliance:

This appliance can be used in cases where snoring is due to lack of patency of the nasopharyngeal aperture. The posterior ports improve the patency by widening the nasopharyngeal apertures.

5. Tongue retaining appliances:

These appliances include incorporation of an anterior hollow bulb which generates a negative pressure vacuum when the tongue is inserted. The tongue is held forward against the posterior pharyngeal wall opening up the airway. Owing to muscle anatomy, this modifies the position of mandible. Lateral holes are given to facilitate breathing.

Here are intraoral and extraoral tongue retaining appliances.

6. Mandibular advancement appliances:

They aid in anteroinferior positioning of the mandible which indirectly brings the tongue forward opening up the posterior airway. The repositioning may also stretch and reduce the collapsibility of soft palate. The flexibility of these elastic straps provides unsurpassed lateral movement and overall TMJ comfort.

Other oral appliances for OSA are :- herbst appliance, aveo – tsd appliance, silent nite appliance, somnomed appliance, the silencer, thornton adjustable positioner appliance.

III. RESULTS AND DISCUSSION

CASE REPORT

Materials and Methods :

Patient named Mrs Gajalakshmi of age 43 yrs has reported to department of prosthodontics of Lenora institute of dental sciences with the chief complaint of snoring, Nocturnal awakening, tiredness on waking up and Excessive sleepiness during daytime. There is no past relevant medical history and her dental history reveals that the patient had undergone extractios at irregular intervals of time with no complications.

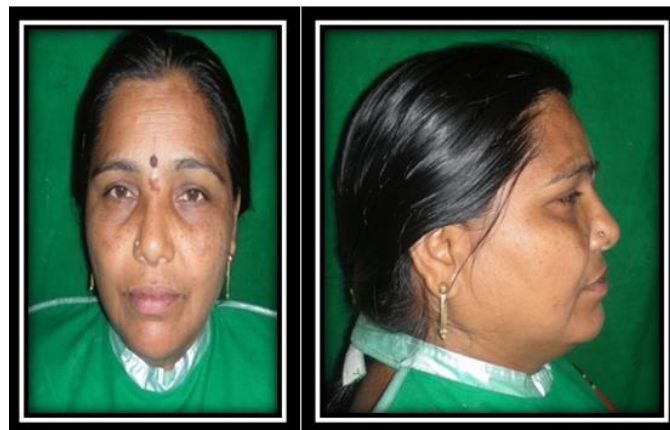

Figure 2 : Frontal and Lateral View Of Patient

Intraoral view

On intraoral examination there is a FPD present extending from 15 to 17, Missing 24,25,36,37,45,46 and 47. Patient has a open bite. Indentations present in the lateral borders of tongue.

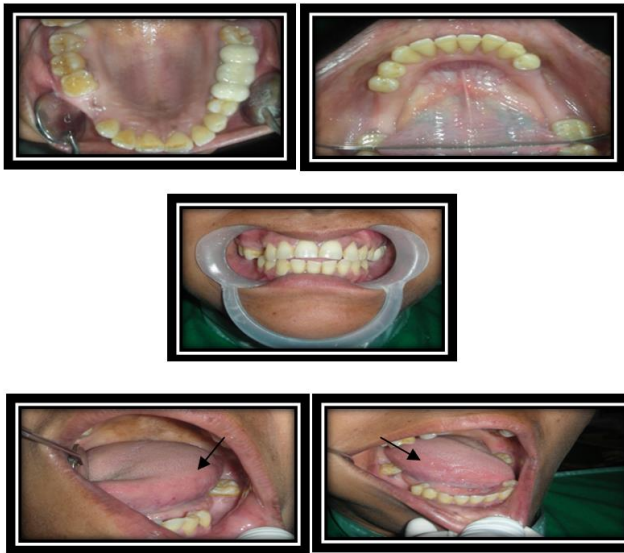

Figure 3 : Intraoral View

Epsworth sleepiness scale (ESS)¹

The ESS (fig 3) which is a self-administered questionnaire with 8 questions. It provides a measure of a person's general level of daytime sleepiness, or their average sleep propensity in daily life. This patient score is 12 which indicates that the patient is moderate sleep apnea patient. Due to the incompetency of soft palate and tongue, PLA is selected as a mode of treatment choice.

Primary Impression

Primary impression is made with alginate for both maxillary and Mandibular arches(Fig 4).

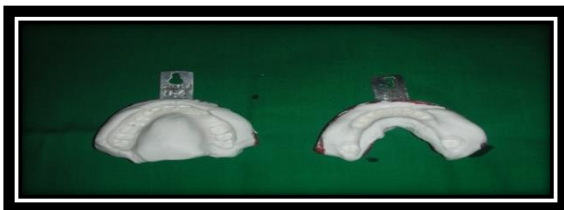


Figure 4 : Primary Impressions for Maxillary and Mandibular arch

A treatment partial denture is fabricated for both maxillary and Mandibular arch

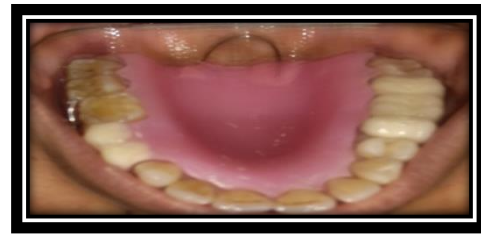

Figure 5 : Treatment Partial denture with retentive loop

The second step in the fabrication is the processing of acrylic framework with posterior wire extension(fig 5). A primary requirement for successful palatal lift is retention. Abutment teeth should be strategically located to give maximum advantage to the lift. The wire framework or retentive loop for the lift should extend 2 cm posterior to the fovea palatine. This length will provide adequate support for lift molding. The loop should be on the same plane as the hard palate. It should be in contact with and slightly displacing the soft palate. The oral portion of the appliance with loop is tried in and adjusted as necessary to ensure complete seating. Modelling compound is applied to the loop, shaped, flamed to create a smooth surface and then chilled before placing it into the mouth. If softened compound is placed in the mouth, the soft palate will displace it downward and the lift action will not occur. Displacement of the soft palate is the primary goal of the procedure and can be accomplished with hardened compound only. Small additions of green stick compound is made posteriorly until the soft palate is brought into light contact with posterior pharyngeal walls (Fig 6). Following each addition, the patient is asked to breathe through nose. Following lift generation session, the lift portion of the appliance is replicated in acrylic resin(Fig 7)

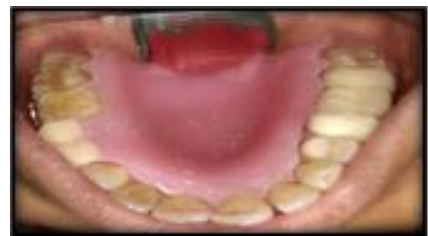

Figure 6 : Green stick compound is added to generate palatal lift



Figure 8 : Impression compound replaced with acrylic resin

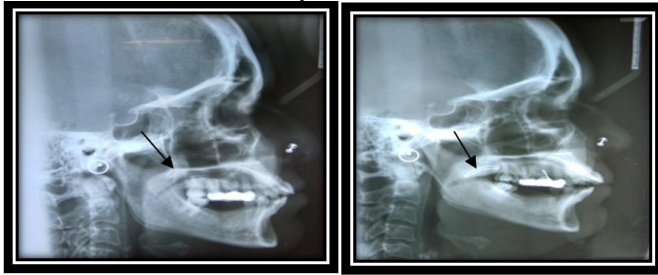


Figure 8 : Lateral Ceph showing Palatal Lift

Discussion

Battagel et al.⁴ (2005) performed sleep nasendoscopy by advancing the mandible by 4–5 mm to simulate the effect of the mandibular appliance. This procedure may help to determine whether a particular patient is a candidate for oral appliance therapy. Ng et al⁵(2006) measured upper airway pressures during natural sleep in patients with obstructive sleep apnea to identify the site of airway collapse and found that oropharyngeal, rather than velopharyngeal collapse, was predictive of the beneficial response to oral appliance. Nordgard S et al⁶ (2006) evaluated the initial short-term effectiveness of palatal implants in treating patients with mild to moderate obstructive sleep apnea (OSA) and found it to have significant improvement. Levirin et al⁷(2014) used Rapid maxillary expansion in modifying the breathing pattern in mouth-breathing patients in order to promote the restoration of physiological breathing. In the current case Palatal lift appliance is fabricated and given to the patient. It significantly

improved the patient condition which is evident on lateral cephalometric radiograph.

IV. CONCLUSION

As dental professionals, we have a significant role to play in the early diagnosis, management and care of patients suffering from sleep Apnoea. Oral appliances play a major role in the non-surgical management of OSA and have become the first line of treatment in almost all patients suffering from OSA. The simplicity and cost of the custom palatal lift appliance makes its use applicable to a wide range of patients for the potential preservation of oral structures. Hence, we should familiarize ourselves with this treatment modality.

V. REFERENCES

- [1]. Greene CS, Laskin DM. Treatment of TMD's: Bridging the gap between advances in research And clinical patient management. Ch.5. Quintessence publishing Co: New delhi; 2013. p.57-60
- [2]. Tsara V Definition and classification of sleep related breathing disorders in adults. Hippokratia. 2009 13(3): 187–191.
- [3]. Barabde AS., Principles of prosthodontic management of sleep Apnea syndrome. Heal talk 2015;7(3);16-9
- [4]. Battagel JM, Johal A, Kotecha BT (2005) Sleep nasendoscopy as a predictor of treatment success in snorers using mandibular advancement splints. J Laryngol Otol 119:106–112
- [5]. Ng AT, Qian J, Cistulli PA (2006) Oropharyngeal collapse predicts treatment response with oral appliance therapy in obstructive sleep apnea. Sleep 29:666–671
- [6]. Nordgard S, Stene BK, Skjostad KW. Soft palate implants for the treatment of mild to moderate obstructive sleep apnea. Otolaryngol Head Neck Surg 2006;134(4):565-70.
- [7]. Levirin K. Rapid maxillary expansion in modifying the breathing pattern in mouth-breathing patients. J Laryngol Otol 2014 119:106–112.
- [8]. Padma A, Ramakrishnan N, Narayanan V. Management of obstructive sleep apnea: a dental perspective. Indian Journal of Dental Research 2007;18(4):201-9.